

Elastography - New Imagistic Method for Assessment of Liver Structure in Children

MARGINEAN Oana¹, BRANZANIUC Klara², MARGINEAN C., PITEA Ana Maria¹, AZAMFIREI Leonard⁴, LUDMILA Bologa⁵, LUDMILA Cerempei⁵, NINEL Revenco⁵

¹ University of Medicine and Pharmacy Tg.-Mures, Pediatrics

² University of Medicine and Pharmacy Tg.-Mures, Anatomy

³ University of Medicine and Pharmacy Tg.-Mures, Gynecology

⁴ University of Medicine and Pharmacy Tg.-Mures, Anesthesiology

⁵ University of Medicine Nicolae Testemiţeanu, Chişinău, Pediatrics Departement

Abstract- Elastography is a new method based on ultrasound imaging, which allows assessment of tissue structure in terms of their stiffness, useful in exploring various organs and systems.

Objectives and aim Study of liver tissue elasticity in children by real-time elastography in normal (healthy children) and in the context of certain disease.

Material and method Our study (prospective type) was carried out at the Ist Pediatric Clinic Tg.-Mures, Romania in the period 2010, September - 2011, April. An ultrasound machine Siemens S 2000 with an up-to-date soft was used for the elastographic assessment of liver by ARFI (Acoustic Radiation Force Impulse Imaging) technique, using "Virtual Touch (VT) Tissue Quantification" technology (for quantification of fibrosis) in children: a lot of different conditions (various liver injuries) and a control group (healthy). The degree of tissue stiffness was expressed as a numerical value called SWV (shear wave velocity), measuring at the level of 8 and 1 liver segments, to highlight differences depending on anatomical structure, but also differentiated on pathology (ie healthy versus those with particular injuries). Measurement data were correlated with biochemical parameters.

Results. Higher SWV-values were found in group with liver-damage ($p=0,04$). Aspartate transaminase and alanine transaminase were statistically significant different between the groups; transaminases increased parallel with SWV (fibrosis degree) in children with liver damage.

Conclusion: Elastography completes diagnostic possibilities, providing information on the degree of hepatic elasticity (even degree of fibrosis), with special importance in liver imaging in adults, but also in pediatric practice.

Key words: elastography, ultrasound, liver, children

I. INTRODUCTION

Ultrasound elastography have the potential to measure the mechanical properties of the tissue displacement through imaging (strain) while under tension [1].

Newly, acoustic radiation force impulse (ARFI) elastography has been introduced as a noninvasive technique for evaluating liver fibrosis [2,3,4].

The ARFI imaging technique uses high-intensity, short-duration acoustic pulses to produce shear-wave propagation in the targeted tissue [5,6]. Shear-wave velocity are measured by repeating push pulses and detection pulses across a user defined ROI (the region of interest) [6,7].

The elastographic ARFI tehnology can be used to measure a numerical value of the wave speed SWV (shear wave velocity) by implementing the Virtual Touch tissue quantification; an image of the used soft-ware is a qualitative gray-scale map of the relative tissue stiffness (elastogram) for a ROI. The smaller the liver tissue elasticity, the higher the SWV. Thus, on elastograma the shining regions correspond to the tissue which is more elastic (less stiff) and the dark regions correspond to the stiff tissue [7].

According to recent reports, ARFI elastography results were similar to transient elastography (TE) regarding correlation with fibrosis stage (histologically) and for diagnosis of moderate fibrosis and cirrhosis [2,3]. The technique showed better diagnostic performance than visual assessment by experienced radiologists for detection of chronic liver disease, while for the evaluation of severity of

chronic liver disease the reported results were the same [6]. The main difference between ARFI and TE elastography is that it is integrated into a conventional ultrasound device [6].

Liver injury in children, in evolution of chronic diseases, including malignancies, viral or autoimmune chronic hepatitis (with B, C, D, E hepatitic virus or cytomegalovirus), alfa-1-antitripsin deficiency, the Wilson disease, as well as liver damages in context of obesity (non-alcoholic fatty liver disease, NAFLD) and drug-related hepatotoxicity are important concerns for practicing pediatricians.

The evaluation of liver damage (which could be of hepatocellular-type, cholestatic or mixed) implies the *clinical findings* (signs of liver damage as nausea, fatigue, anorexia, cholestatic signs as jaundice, pruritus), *laboratory investigations* (increased transaminases and increased alkaline phosphatase, bilirubin and albumin levels determination) [8], *imagistic tests*, (abdominal ultrasonography and computerised tomography), the *flow on portal vein* evaluation.

Liver biopsy has been the gold standard for fibrosis staging. However, this invasive method, with a lot of secondary effects which can cause serious complications such as intraperitoneal bleeding and mortality is about 1 in 1000 [6,9], hardly accepted by children and parents [3]. In clinical practice as well as on research line, there are constantly evaluating diagnostic techniques of hepatic evaluation in order to find non-invasive alternatives to

replace hepatic biopsy but to accurately assess the degree of fibrosis.

Ultrasonography is usually the first-line investigation in the assessment of patients, considering its low cost, non-invasiveness, repeatability and easy access; MRI and PET, and often CT, are restricted to selected cases, due to their limited availability and high costs.

Thus, the introduction of new techniques to increase the sensitivity of US, such as real-time elastography would be a major advantage.

The aim of the paper was the study of the liver tissue elasticity, assessed by real-time elastography, in correlation with biochemical parameters (namely transaminases levels) in children with different causes of liver injury (obesity, hepatitis, liver damage in children with malignancies under/after-chemotherapy, drug-related hepatotoxicity) versus children with normal biochemical parameters regarding liver function.

II. MATERIAL AND METHODS

The present study was carried out at the Ist Pediatric Clinic Tg.-Mures, Romania, between 2010 September and 2011, April; it was a prospective study including a control group composed of 38 children with normal clinical and paraclinical findings related to the liver function and a lot of 96 children with different causes of hepatopathies, selected based on clinical signs and symptoms of liver damage (abdominal discomfort, fatigue, anorexia, nausea, vomiting, jaundice, pruritus, hepatomegaly, ascites), changes in laboratory findings (liver tests considering the synthetic function, hepatocellular necrosis and cholestasis) and/or abnormalities in liver imaging.

An informed consent was signed by legal tutors of each patient at the moment of hospitalization in our clinic (in accordance with the principles of the Helsinki declaration). Combined B-mode US/ARFI elastography was performed using an ultrasound machine Siemens S 2000 with an up-to-date soft, using a transducer array operating at 4,1 MHz by an experienced radiologist with 11 years of experience in ultrasonography.

The patients were placed supine with the right arm straight over head.

SWV (m/s) were measured in the area of interest chosen by the examiner. Measurements were performed in the right lobe, especially in the 8th segment, 4 cm under the skin, at 2.5-4.5 cm depth, under the liver capsule (which has been avoided, being an fibrous tissue rich area). Also, the caudate lobe of the liver (the 1st segment) was examined in order to evaluate the elasticity in the right versus the left liver lobe.

There have been made 10 measurements in a selected region, and median velocity values were obtained through calculation in Microsoft Excel program.

For continuous variables, mean values were expressed as mean \pm standard error of mean (SEM) or Standard Deviation (SD).

Statistical analysis were performed using Graph Pad Prisma and Graph Pad InStat Demo programs. Student test, Chi square (χ^2), Fisher exact test, ANOVA test were used; correlation between average SVW and study variables (transaminasis) were assessed based on Pearson correlation coefficient (r). The threshold of significance was $p < 0.05$.

III. RESULTS

In group of patients with liver damage there were 28 overweight and obese children (considered overweight

whether their weight was between the 85th and 95th percentile for age and sex, and obese whether their weight exceeds 95th percentile, respectively), all of them with modifications to the standard abdominal ultrasound (high echogenicity, granular liver aspect, posterior attenuation suggestive for steatosis); there were 48 patients with various malignancies under or after chemotherapy, with tumor infiltration of the liver or hepatotoxicity related to cytostatic treatment and a number of 20 patients with various etiology of hepatopathy (viral hepatitis, acute toxic hepatitis, drug hepatotoxicity) (as presented in Figure 1).

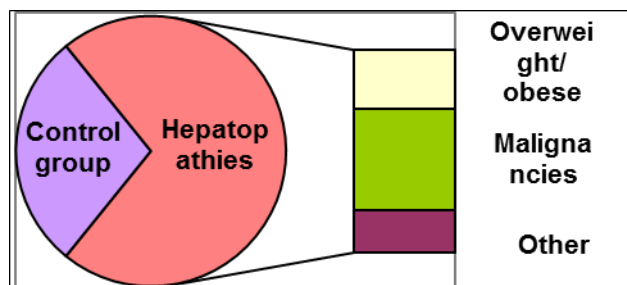


Fig. 1. The structure of the three groups (by condition)

Descriptive statistics show averages \pm standard deviations (SD) of study groups. In the control group the average elasticity was $1,18 \pm 0,28$ m/s; in the group of children with different causes of liver diseases, elasticity was $1,39 \pm 0,41$ m/s. Alanine transaminase (ALT, IU) was $19,56 \pm 8,67$ SD in the control group, and $37,42 \pm 31,16$ in the group of children with liver diseases, while aspartate transaminase (AST, IU) was $24,88 \pm 8,67$ SD in the control group, and $39,92 \pm 20,12$ in the group of children with liver injury.

Comparing liver tissue elasticity values between the groups higher speeds were found in groups with liver damage, the differences being statistically significant at CI of 95%. We've got a statistically significant difference with $p = 0.0044$ (Figure 2).

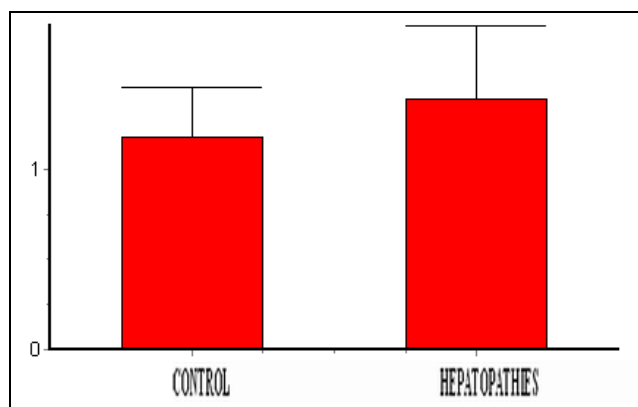


Fig. 2. Comparison between the median SVW of the groups

Regarding alanine transaminase (ALT, IU), as expected, the levels were higher in group of children with liver diseases, the difference from control was statistically extremely significant, with $p < 0.0007$ (Figure 3).

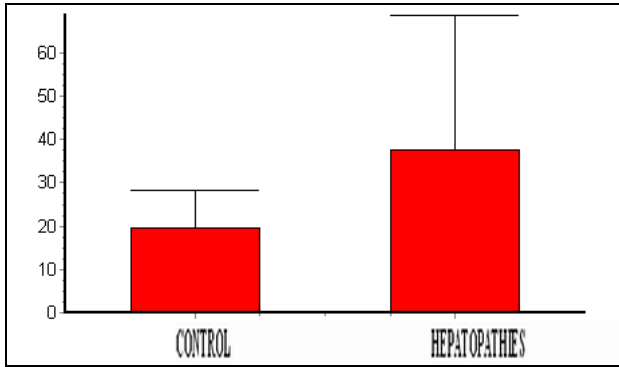


Fig.3. Comparison between the median ALT of the three groups

As far as it concerns aspartate transaminase (AST, IU), in the control group it were, also, smaller levels than in the group of children with hepatopathies, the difference between AST mean for the two groups was, as for ALT, statistically extremely significant, with $p < 0.0001$ (Figure 4).

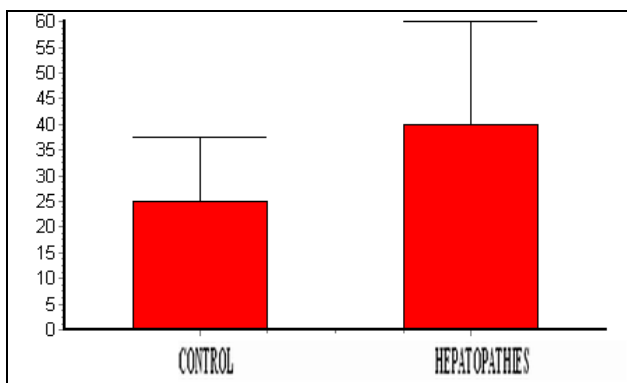


Fig. 4. Comparison between the median AST of the three groups

We searched for correlations between global SVW and other determined parameters (AST and ALT) in each group, but we obtained no statistically significant correlations between the assessed parameters, except that between SWV and AST, only for the group of children with liver injury ($r = 0,54$ and $p = 0,01$), statistically significant.

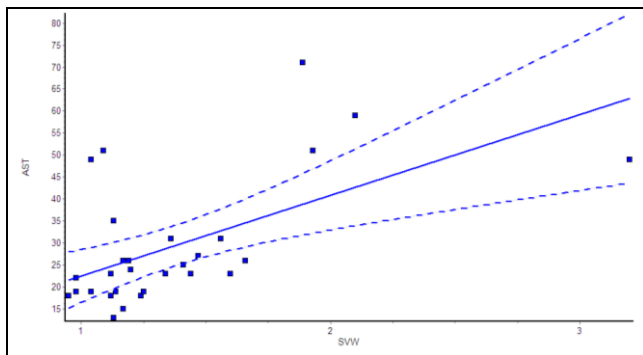


Fig. 5. The correlation between the values of SVW and AST average in group of children with liver damage

The classical descriptive anatomy nomenclature distinguishes four lobes: right, left, caudate and quadrate, concept which does not reflect the functional anatomy [10].

According to the International Anatomical Nomenclature, a posterior and anterior segment are attributed to the right lobe, and a medial and lateral segment to the left lobe, each of these segments being divided into an antero-inferior and a postero-superior segment, so as liver has eight segments, numbered clockwise from I to VIII [11].

Segment 1 (caudate lobe or Spiegel lobe) is a distinct structure of the liver, receiving blood flow from both the right and left-sided vascular branches; a special vascularization which represents the distinctive characteristic of segment 1 [11,12].

The caudate lobe is less echogenic.

Assessing liver elasticity separate for each segment for the entire group (all 134 patients in the study), comparing the SVW values by Mann-Whitney test for liver tissue elasticity there was found no statistically significant differences between segment 1 (caudate lobe) and segment 8 (right lobe), ($p=0,1583$).

Evaluation of each segment revealed for the control group a median SWV for *segment 8* of $1,24 \pm 0,31$ m/s, while for *segment 1* SWV was $1,06 \pm 0,3$ m/s; by applying the Student T Test between the media of SVW on those two segments (unpaired t test), we obtained a statistically significant difference ($p < 0,0121$, Figure 6).

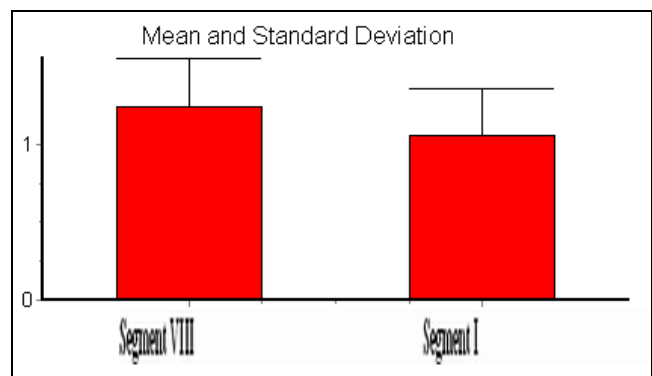


Fig. 6. Comparison between mean values of SVW on segment 1 and segment 8 in the control group.

In group of children with hepatopathies, SWV was $1,30 \pm 0,47$ m/s in *segment 8*, and $1,31 \pm 0,5$ m/s in *1st segment*, without statistically significant difference when applying the Student T Test between the media of SVW on those two segments (unpaired t test) ($p = 0,8866$).

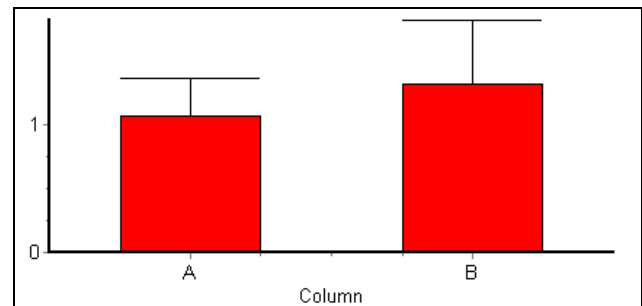


Figure 5 - Comparison between the average SWV in segment 1 between controls and the group with hepatopathies

No statistically significant differences were obtained between *control* group and the one with *hepatopathies* when applying the Student T Test for SWV values in the 8th segment ($1,24 \pm 0,31$ m/s versus $1,30 \pm 0,47$ m/s), with $p = 0,4691$.

For the 1st segment, comparison between the average SWV of the *controls* ($1.06 \pm 0,3$ m/s) versus group with *hepatopathies* ($1,31 \pm 0,5$ m/s), performed by Student T test, achieved a very significant difference ($p=0,0046$ -Figure 5).

IV. CONCLUSIONS

In children with liver damage, compared to the control group, transaminase levels increased as well as SWV and therefore the degree of fibrosis.

We found that SWV is higher in children with liver-diseases, globally, meaning that any tissue injury result in changes of the liver elasticity up to fibrosis.

In normal conditions (children with free liver tissue), SVW was higher for the segment VIII compared to I, statistically significant, meaning that caudate lobe is "softer", difference that does not exist in the group of liver diseases.

SWV values in group of children with hepatopathies were found to increase particularly in the segment I (caudate lobe), which shows that it is first affected by any liver injury.

Faithful evaluating the elasticity, real-time elastography has a certain role in the evaluation of hepatic vasculature and tissue damages. Due to this fact, elastographic evaluation of liver and particularly in the caudate lobe has further implications for assessment of liver fibrosis and would have possible utility in preparation and management in cases of liver transplantation.

Ultrasound elastographic assessment, by new technologies available, through ARFI quantification respectively, may enhance the current role of liver ultrasound for patients with liver disease.

„This paper is partially supported by the Sectoral Operational Programme Human Resources Development, financed from the European Social Fund and by the Romanian Government under the contract number POSDRU/89/1.5/S/60782”

This paper is partially supported by the project NASR 421/2010: "Correlations between the elasticity of the caudate lobe and other lobes of the liver in children by real-time elastography, with implications for liver transplantation”

REFERENCES

- [1] Ophir J, Cespedes I, Ponnekanti H, Yazdi Y, Li X. Elastography: a quantitative method for imaging the elasticity of biological tissues. *Ultrason Imaging*. 1991;13:111
- [2] Friedrich-Rust M, Wunder K, Kriener S, Sotoudeh F, Richter S, Bojunga J, et al. Liver fibrosis in viral hepatitis: Noninvasive assessment with acoustic radiation force impulse imaging versus transient elastography. *Radiology* 2009;252:595–604
- [3] Lupsor M, Badea R, Stefanescu H, Sparchez Z, Branda H, Serban A, Maniu A. Performance of a new elastographic method (ARFI technology) compared to unidimensional transient elastography in the noninvasive assessment of chronic hepatitis C. Preliminary results. *J Gastrointest Liver Dis* 2009;18:303–310
- [4] Takahashi H, Ono N, Eguchi Y, Eguchi T, Kitajima Y, Kawaguchi Y, et al. Evaluation of acoustic radiation force impulse elastography for fibrosis staging of chronic liver disease: A pilot study. *Liver Int* 2010;30:538–545
- [5] Palmeri M, Wang M, Dahl J, Frinkley K, Nightingale K. Quantifying hepatic shear modulus in vivo using acoustic radiation force. *Ultrasound Med Biol* 2008;34:546–558.
- [6] Kim J. E. Lee J.Y., Kim Y.J., Yoon J.H., Kim S.H., Lee J.M., Han JK, et al. ARFI elastography for chronic liver disease: Comparison with ultrasound-based scores of experienced radiologists, Child-Pugh scores and liver function tests. *Ultrasound in Medicine and Biology* 2010;36(10):1637-43
- [7] Lazebnik R.S. *Ultrasound, Mountain View, CA USA Tissue Strain Analytic, Virtual Touch Tissue Imaging and Quantification*. Siemens Medical Solutions, USA, Inc., 2008
- [8] Roberts E.A. Drug-induced liver disease. In Suchy F.J., Sokol R.J., Balistreri W.F., (Eds). *Liver Disease In Children*, Third Edition. Cambridge University Press, Cambridge, New York, 2007;478-512
- [9] Bravo AA, Sheth SG, Chopra S. Liver biopsy. *N Engl J Med* 2001;344:495–500
- [10] Strunk H., Stuckmann G., Textor J., Willinek W. Limitations and Pitfalls of Couinaud's Segmentation of the Liver in Transaxial Imaging. *European Radiology* 2003;13(11):2472-2482, DOI: 10.1007/s00330-003-1885-9
- [11] Dodds WJ, Erickson SJ, Taylor AJ, Lawson TL, Stewart ET. Caudate lobe of the liver: anatomy, embryology and pathology. *AJR* 1990; 154: 87-93
- [12] Brown BM, Filly RA, Callen PW. Ultrasonographic anatomy of the caudate lobe. *J Ultrasound Med* 1982; 1: 189-192