

DOI: 10.5281/zenodo.3784358
CZU 681.586



SYNDROME OF THE TREPHINED AND CUSTOM MADE CRANIOPLASTY USING VIRTUAL SURGICAL PLANNING. A SERIES OF 10 CASES

Andrei Peciul¹, ORCID ID: 0000-0002-9796-8872,
Stanislav Strîșca^{2*}, ORCID ID: 0000-0002-6215-9434,
Constanța Dogaru¹, ORCID:0000-0001-5976-8215,
Dumitru Sîrbu², ORCID:0000-0003-4023-4031,
Victor Șontea³, ORCID: 0000-0002-0372-8799,
Evelina Savițchi³, ORCID: 0000-0001-8987-7287

¹Institute of Emergency Medicine, Neurosurgery Department, 1, Toma Ciorbă st., MD-2004, Chișinău, Republic of Moldova

²State University of Medicine and Pharmacy, Department of oral and maxillofacial surgery and oral implantology "Arsenie Guțan", 1, Toma Ciorbă st., MD-2004, Chișinău, Republic of Moldova
Institute of Emergency Medicine, Department of oral and maxillofacial surgery and oral implantology "Arsenie Guțan", 1, Toma Ciorbă st., MD-2004, Chișinău, Republic of Moldova

³Technical University of Moldova, Microelectronics and Biomedical Engineering Department, 9/7, Studentilor st., MD-2045, Chișinău, Republic of Moldova

*Corresponding author: Stanislav Strîșca, stanislav.strisca@gmail.com

Received: 03.23.2020

Accepted: 04. 30. 2020

Abstract. Cranial defects often occur after trauma, neurosurgical procedures like decompressive craniotomy, tumor resections, infection and congenital defects. Because prosthesis production is often costly and requires complex intraoperative processes, this paper reviews clinical data of syndrome of the trephined and its treatment by means of cranioplasty with the application of newer technologies such as virtual surgical planning, computer-aided design, as well as computer-aided manufacturing in order to give the opportunity to fabricate custom-made polymethylmethacrylate implants. Implant customized manufacturing for cranioplasty allows for a precise and anatomical reconstruction in a shorter operating time compared to other conventional techniques. We present a simple protocol, low-cost method for prosthesis manufacturing that ensures surgical success. In this case series on 10 patients with cranial defects are presented to describe the digital technique. In an open-source software's virtual prosthesis is designed and manufactured with the aid of 3D-printing technology. Then the anatomical model, designed plate and the tow molds are printed using a DLP 3D printer, which then is used in a laboratory to cast the final customized prosthesis in polymethyl methacrylate (PMMA).

Keywords: *syndrome of the trephined, cranioplasty, polymethylmethacrylate, virtual surgical planning, computer-aided design, computer-aided manufacturing.*

Introduction

Syndrome of the trephined (SoT) or post-craniectomy syndrome, also known as Sinking skin flap syndrome or Sunken brain syndrome, is characterized by a multitude of neurological manifestations in patients who have experienced the craniectomy procedure and who subsequently regressed after performing cranioplasty. SoT was first described by Grant and Norcross in 1939 [1]. SoT predisposes to male sex (~ 60%) and occurs more frequently after decompressive craniotomies due to craniocerebral trauma (~ 38%). As a rule, SoT starts in approximately 5-10 months after-surgery [2]. Cranioplasty dates back to the ancient period (7000 BC) as well as trepanation [3] and is defined as the full-thickness reconstruction of calvarial bone. Large skull defects (> 25 cm²) are reconstructed to protect the underlying brain, shield the brain from infection, and correct esthetic deformities [3]. However, it is unclear whether reconstruction is appropriate for the treatment of „syndrome of the trephined” or to decrease seizure activity [4].

This procedure is also performed to treat growing skull fractures and congenital anomalies in pediatric patients, where the skull reconstruction is more challenging, considering the singularly rapid bone growth in children [3]. The pathophysiological mechanism of SoT has not been fully elucidated, but at the moment the influence of the following factors is considered: action of the atmospheric pressure on the brain that affects the cerebral perfusion on the defect surface; migration of the cerebrospinal fluid (CSF), which causes edema of the brain tissue underlying the cranial breach (demonstrated by the increased incidence of hygromas in the first month after decompressive craniectomy); global reduction of cerebral blood flow (CBF) not only at the level of the breach but also at a distance (demonstrated by CT-perfusion with Xe), caused by the atmospheric pressure and damage to venous drainage; alteration of glucose metabolism in the affected hemisphere and consequently causing cortical dysfunction [5]. Neurological manifestations of SoT patients include: motor deficiency 61%; cognitive disorders 44% (37,5% concentration deficit, 37,5% amnesic disorders); dysphasic disorders 29,6%; disturbance of the state of consciousness 27,8%; headache 20,4%; seizures 11,1%; local pulsatile pain; insomnia; irritability [1]. The time frame for maximum neurological recovery is 2,9-3,4 months [1]. Postcranioplasty 19,6% of patients achieve functional independence, cognitive disorders improve at 9,8% and 10,3% partially recover the motor deficit.

Cranioplasty is indicated for the purpose of removing the aesthetic defect, remission of SoT, as well as protection against traumatic agents. As a rule, choosing the right time to perform the cranioplasty is at 4 months post-craniectomy decompression due to spontaneous intracerebral hematoma or closed cranio-cerebral trauma and 6 months after decompressive craniectomy or open cranio-cerebral trauma in order to reduce the risk of infectious complications.

The reconstruction of the craniofacial skeleton is often difficult to perform even for an experienced surgeon, critical factors contributing to the complexity of the construction include anatomy, the presence of vital structures, and the uniqueness of each defect [6]. Surgical procedure of cranioplasty presents the following risks of postoperative complications: damage to the underlying brain tissue, increase of intracranial pressure immediately after application of implant, infection - 10%, hematoma in the lodge - 7%, convulsive seizures - 14%, hydrocephalus - 13%, resorption of bone grafts, paradoxical herniation and severe cerebral edema.

The various materials used for cranioplasty are methyl methacrylate, hydroxyapatite, titanium, polyethylene, and allogenic and autologous bone, of which polymethylmethacrylate (PMMA) and titanium are most commonly used [7]. The use of synthetic materials for cranioplasty became popular after World War II. The ideal characteristics of prosthetic materials are their inability to cause inflammatory reactions, non-allergenicity or inability to cause hypersensitivity, chemical inertness, non-carcinogenicity, ability to withstand strain and tension, capacity to be sterilized and to be molded into the desired shape when fabricated [8].

Today, both titanium and PMMA are widely used alloplastic materials. However, titanium prosthesis has some disadvantages, for example, thermal conduction, little chance of intraoperative modifications and a high cost [9]. The advantages of PMMA are the following: it is low cost, no donor is required, it is lightweight, strong, inert, radiolucent, non-ferromagnetic and stable [10]. The disadvantages are that it has a low adherence to the surrounding tissue, it may cause tissue reactions (subcutaneous seroma), and may be bulky in some areas like the orbital rim [11]. When using conventional treatment methods, these specific features create drawbacks in the process of restoring skull integrity.

Alloplastic materials, including polymethyl methacrylate (PMMA), hydroxyapatite and titan mesh, have been proposed as malleable substituents, which can be configured intraoperatively. The above-mentioned materials may require various additional intraoperative manipulations and therefore present some drawbacks: increasing the intraoperative time; adapting the material to the contour of the defect, which is difficult and imprecise, often leading in unaesthetic results especially in patients with extensive or complex defects; direct contact of the PMMA implant with dura mater during exothermic reactions with the release of toxic monomers affects adjacent tissues and can produce both local and systemic reactions.

In order to overcome the shortcomings of intraoperative molding, many techniques have been introduced for the prefabrication of customized cranioplastic implants using medical imaging and three-dimensional (3D) biomodeling [12]. Today, three-dimensional (3D) models of anatomical structures can be reconstructed based on anatomical information from scanning data coming from computerized tomography (CT), magnetic resonance imaging (MRI), positron emission tomography/CT (PET/CT). Advances in hardware and software have increased the feasibility of accurate 3-D CAD reconstruction of skull skeletons [13, 14].

The development of virtual surgical planning (VSP), computer-aided design (CAD) and computer-assisted manufacturing (CAM) technologies offers the possibility of obtaining custom implants adapted to each defect. Prefabrication of alloplastic implants using VSP, CAD / CAM technologies, which are adapted to individual patient defects, clearly improve the aesthetic results, reduce the duration of intervention with decreased hemorrhage and the risk of infection, preventing the toxic action of the monomer [15].

The CAD/CAM systems also allow to design and manufacture personalized implants at an affordable cost and within a reasonable time.

Here we present our preliminary experience in a clinical series of 10 patients who underwent "custom-made" cranioplasty, using an alternative method of designing and manufacturing, together with the support of a skull computed tomography (CT) scan to model the complex-shaped PMMA specific implant, with the use of a plastic mold.

Purpose: To assess an alternative method of PMMA patient specific implant fabrication of acquired cranial defect with the use of contemporary virtual surgical planning, computer-assisted design and computer-assisted-manufacturing technologies.

Materials and Methods:

Patients

From May 2017 to April 2020, 10 patients underwent aforementioned cranioplasty at the Institute of Emergency Medicine, Neurosurgery Department. A total of 10 cranial implants were inserted, all prefabricated made of PMMA. The PMMA implants were fabricated by VSP+CAD/CAM technologies.

Fabrication of 3D matrix

The clinical protocol consists of acquiring 3D data of craniofacial complex via multi-spiral computerized tomography or cone beam CT. DICOM (Digital Imaging and Communications in Medicine) data were processed and imported into the *open-source software 3DSlicer 4.8.1* (Figure 1.A.) and, based on density ranges of the Hounsfield units, the 3D model of the region of interest was obtained, the data being exported in the STL format (Standard Tessellation Language) later on. The created virtual patient was imported into the Meshmixer software (Figure 1.C), where the customized implant modelling was performed using the symmetrization process, by acquiring a mirrored image of a healthy region from the contralateral side. The 3D matrix wares obtained by boolean subtraction process of the customized implant. (Figure 1.D). The fabrication of the matrix was performed using the DLP Moonray S100 3D printer (Figure 2.C) (SprintRay, USA).

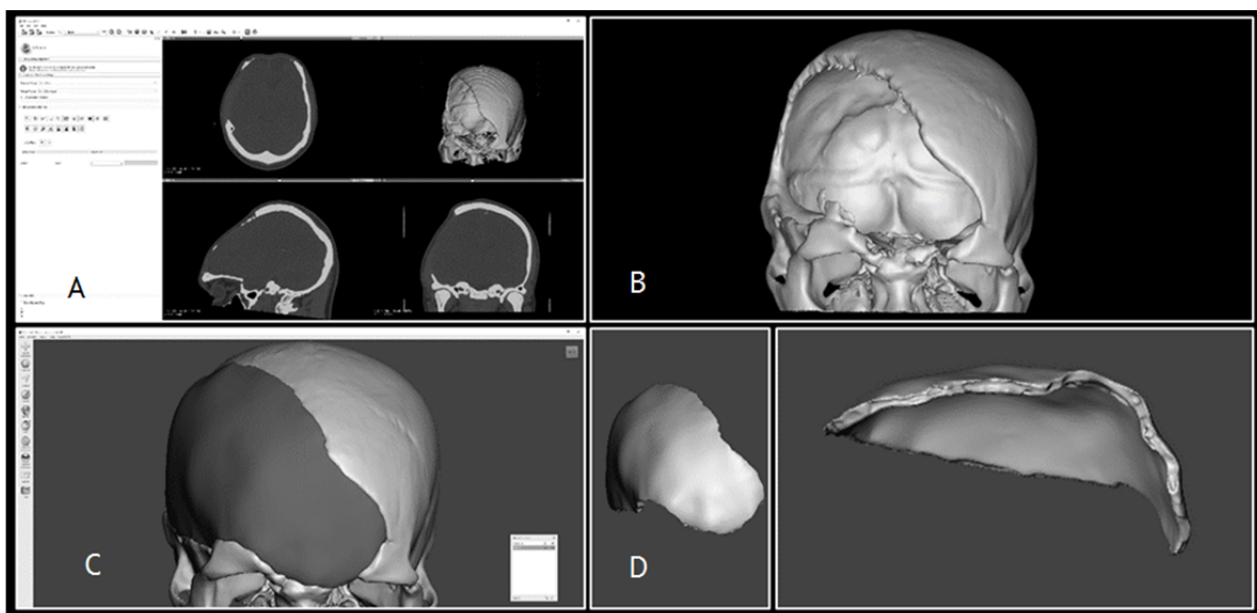


Figure 1. Data collection for virtual planning, conversion of data into 3D images.A) Segmentation of anatomical formations based on density range (Slicer 3D). B) Virtual 3D model. C) The symmetrization of skull using the process of obtaining a mirrored image of the contralateral side. D) The obtaining of virtual implant via the boolean subtraction process.

3D printing process had taken about 6 hours. PMMA resin was prepared by mixing the polymer and the monomer; in the „dough” phase it was introduced into fabricated matrices and compressed between them (Figure 2.D).

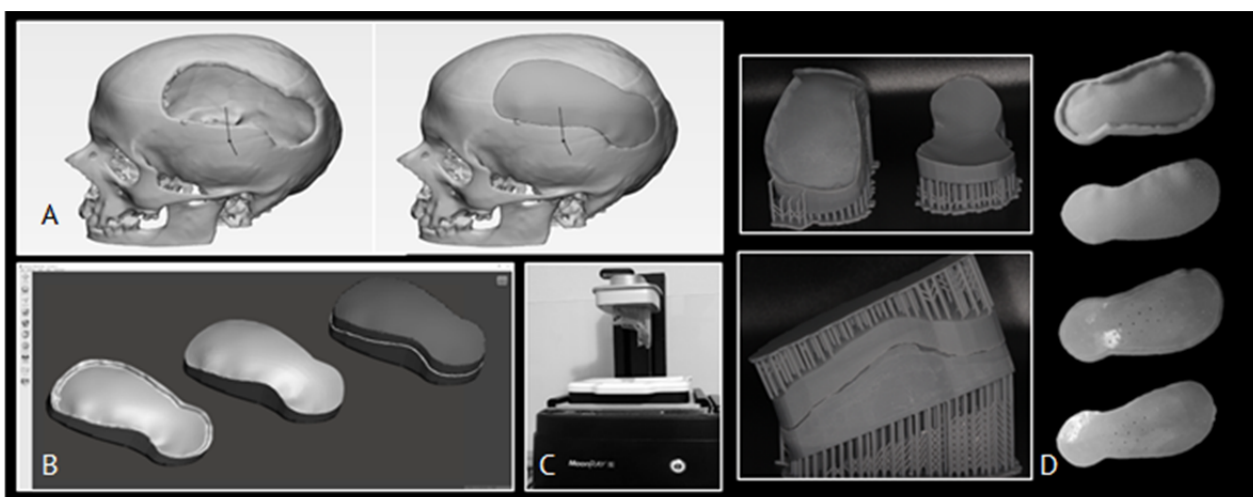


Figure 2. A) Virtual surgical planning of the cranial defect. B) Modelling of matrix and plate based on customized cranial plate within Meshmixer software. C) Printing of 3D matrix and plate using the DLP Moonray S100 printer. D) The matrix, plate, application of PMMA and finishing the customized flap.

To prevent chemical adhesion of the PMMA material to the obtained matrices, they were isolated. At the end of the polymerization phase, the 2 matrices were removed, thus obtaining the custom implant from PMMA. It was followed by the grinding of the implant to the contour of the defect and the drainage and threading holes of the fixing screws. The implants were sterilized using plasma sterilizer, then delivered to the operating room. The cranioplasty surgery involves several stages: after the general anesthesia the patient is positioned, the operative field is processed and delimited, then the incision is made on the path of the old scar, followed by meningoysis with the delimitation of the cranial defect edges, implantation of the custom cranial plate from PMMA, control of hemostasis at all stages and suture in anatomical planes.

Results

All implants were successful. The average duration of the intervention (Figure 3) was on average 120 minutes (minimum-90, maximum-150 minutes). The aesthetic aspect as well as the postoperative computed tomography data showed a good restoration of the cranial symmetry (Figure 4). Despite the implant material used, no signs of postoperative complications occurred during follow-up period (6-34 months). Also to mention, is the fact that, plates made of polymers have the advantage, that their edges can be trimmed for a better fit, avoiding additional trauma to bone in order to correct their borders. PMMA materials seem to manifest good strain distribution, even though it cannot withstand forces endured by Ti alloys (51.328 MPa for the PMMA and 145.146 MPa for the Ti6Al4V) [16], its mechanical strength is sufficient to tolerate higher loads than the native bone tissue.

However, placement of polymer may cause hypersensitivity, because of the slow release of monomers that are known to be toxic. In this study we did not observe such behavior. Even though, we observed good outcomes with prefabricated PMMA implants, there is an ongoing search to identify materials with more favorable characteristics. PEEK materials seem to show excellent long-term biocompatibility properties and should be more studied in the future.

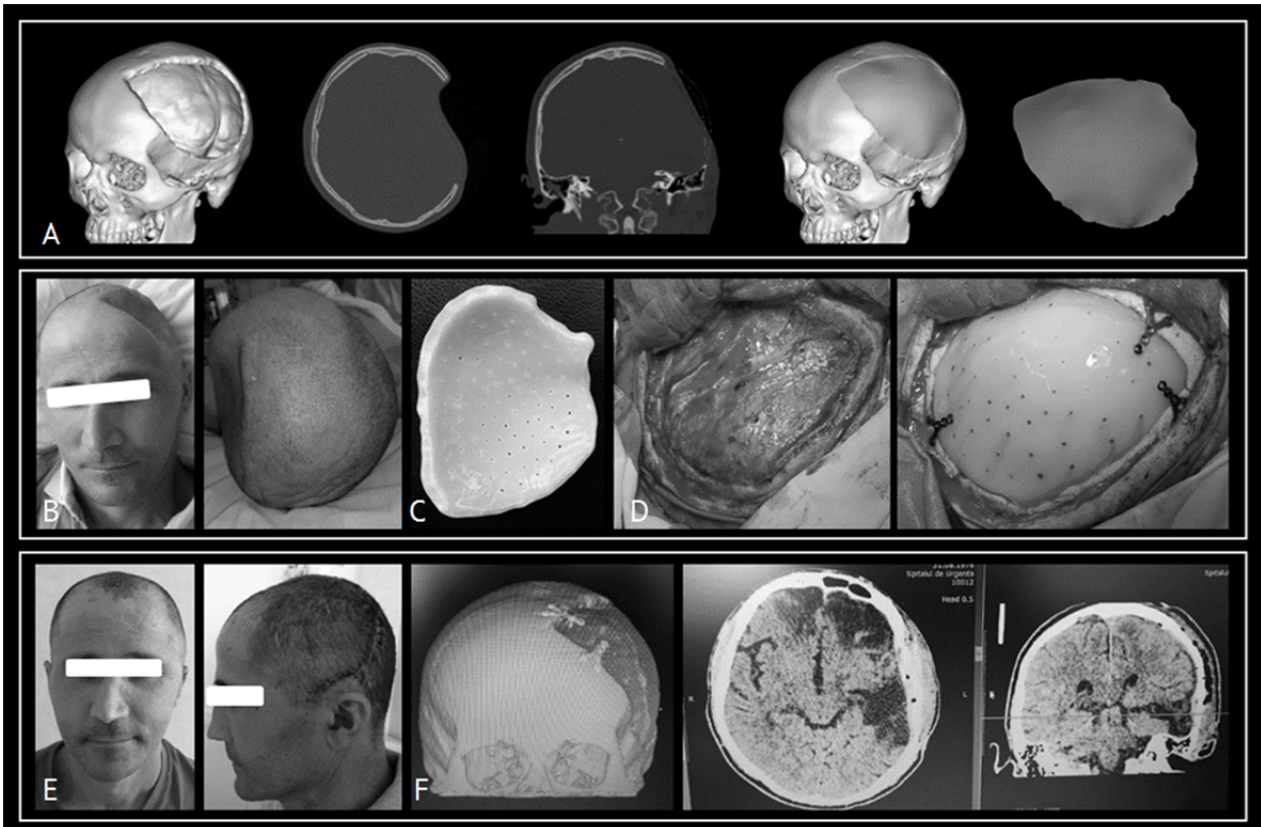


Figure 3. Clinical case. A - preoperative virtual surgical planning and PSI modeling, B - patient with SoT, C - personalized cranial plate from PMMA, D - intraoperative aspect of cranioplasty intervention: the meningolysis stage (left) and implantation of the personalized cranial plate from PMMA (right), E - same patient after cranioplasty surgery, F- postoperative CT images with bone reconstruction.

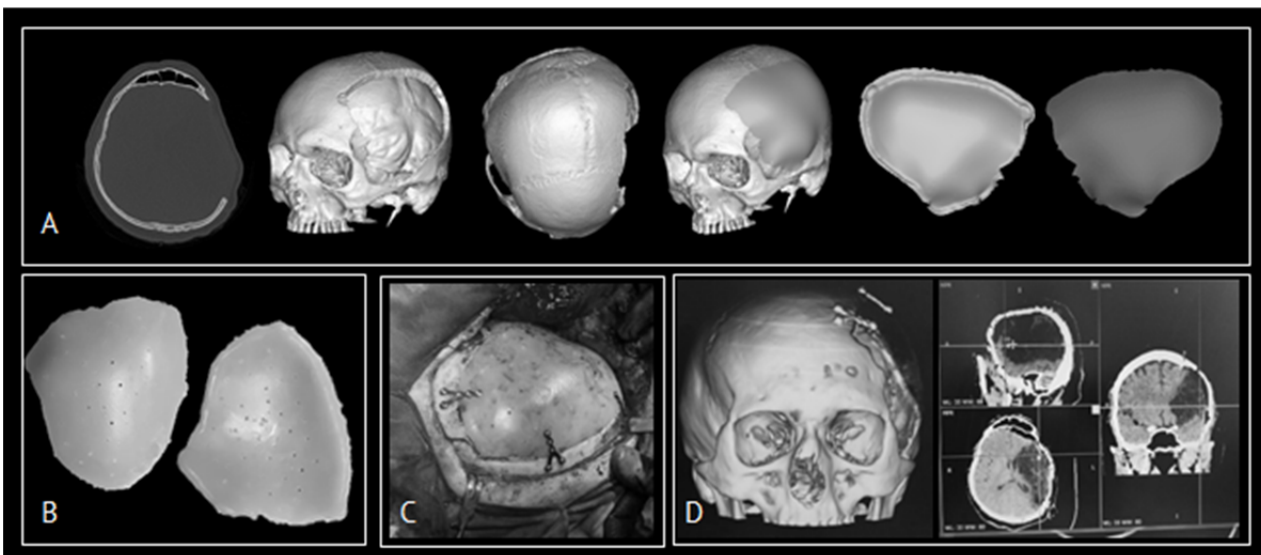


Figure 4. A - patient with SoT, preoperative virtual surgical planning and PSI modeling., B - personalized cranial plate from PMMA., C - intraoperative aspect of cranioplasty intervention., D - postoperative CT images with bone reconstruction.

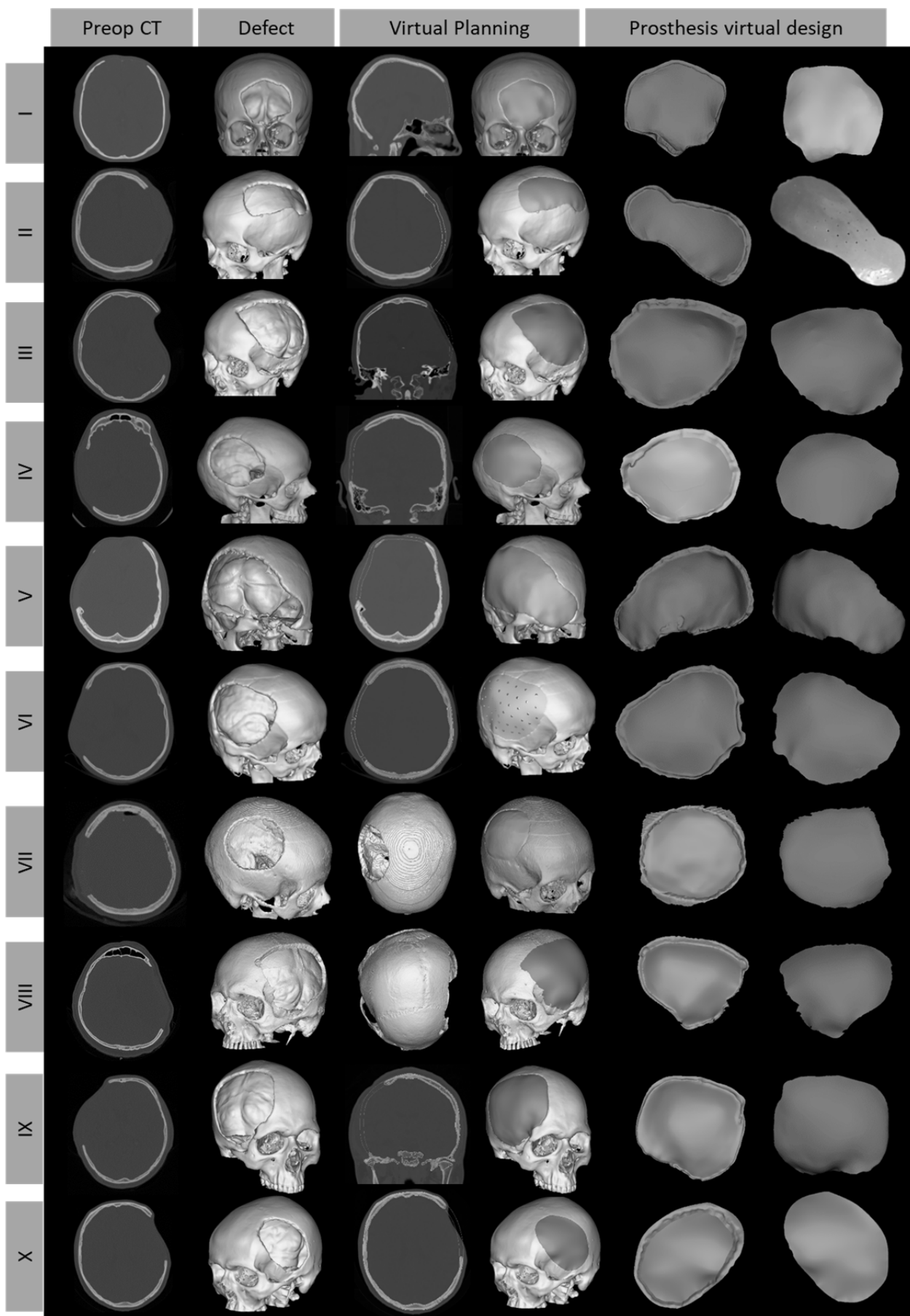


Figure 5. Series of 10 cases in which the technology of virtual surgical planning was applied.

Conclusion: The syndrome of the trephined is a serious complication, which at the moment has no clear definition and requires additional research to elucidate the pathophysiological mechanisms, which could serve as a reference in the timing of surgical treatment and would influence the neurological recovery of the patients with acquired cranial defects. Although metal has been used in cranioplasty since ancient times, contemporary technologies using the 3D printer allow the creation of custom implants made of alloplastic materials such as polymethyl methacrylate, at an affordable cost. Further research calls for the potential of focusing on molecular biology techniques, which would involve bone growth factors to facilitate osteogenesis at the implant level.

References

1. Grant FC., Norcross NC. Repair of cranial defects by cranioplasty. *Ann Surg.*1939;110(4):488-512
2. Aydin S., Kucukyuruk B., Abuzayed B., Aydin S., Sanus GZ. Cranioplasty: review of materials and techniques. *J Neurosci Rural Pract.*2011;2:162–167
3. Bhargava D., Bartlett P., Russell J., Liddington M., Tyagi A., Chumas P. (2010) Construction of titanium cranioplasty plate using craniectomy bone flap as template. *Acta Neurochir (Wien)* 152(1):173–176
4. Joseph V., Reilly P. (2009) Syndrome of the trephined. *J Neurosurg* 111(4):650–652
5. Ashayeri K., Jackson EM., Huang J., Brem H., Gordon CR. Syndrome of the Trephined: A Systematic Review. *NEUROSURGERY.*2016;79(4):525-534
6. Parthasarathy J. Modeling, custom implants and its future perspectives in craniofacial surgery. *Ann Maxillofac Surg.*2014.4(1): 9–18.
7. Harris DA., Fong AJ., Buchanan EP., Monson L., Khechoyan D., Lam S. (2014) History of synthetic materials in alloplastic cranioplasty. *Neurosurg Focus* 36(4):E20
8. Roa TT. Materiales inertes. In: En Coiffman F., editor. *Texto de Cirugía Plástica, Reconstructiva y Estética*, vol. 1. Barcelona: Salvat Editores; 1986. p. 805–8.
9. Neumann A., Kevenhoerster K. Biomaterials for craniofacial reconstruction. *GMS Curr Top Otorhinolaryngol Head Neck Surg.* 2009;8:Doc08.
10. Jaber J., Gambrell K., Tiwana P., Madden C., Finn R. (2013) Longterm clinical outcome analysis of polymethyl-methacrylate cranioplasty for large skull defects. *J Oral Maxillofac Surg* 71(2): e81–e88.
11. Joseph V., Reilly P. (2009) Syndrome of the trephined. *J Neurosurg* 111(4):650–652.
12. Bum-Joon Kim., M.D., Ki-Sun Hong., M.D., Ph.D., Kyung-Jae Park., M.D., Ph.D., Dong-Hyuk Park., M.D., Ph.D., Yong-Gu Chung, M.D., Ph.D., Shin-Hyuk Kang, M.D., Ph.D. Customized Cranioplasty Implants Using Three-Dimensional Printers and Polymethyl-Methacrylate Casting. *J Korean Neurosurg Soc* 52 : 541-546, (2012) 361–370.
13. Bonda DJ., Manjila S., Selman W., Dean D. (2015) The recent revolution in the design and manufacture of cranial implants: modern advancements and future directions. *Neurosurgery* 77(7(5):814–824.
14. Bor-Seng-Shu E., Figueiredo E.G., Fonoff E.T., Fujimoto Y., Panerai R.B., Teixeira M.J. Decompressive craniectomy and head injury: Brain morphometry, ICP, cerebral hemodynamics, cerebral microvascular reactivity, and neurochemistry. *Neurosurg. Rev.* 2013, 36, 361–370).
15. Lambrecht JT., Brix F. Individual skull model fabrication for craniofacial surgery. *Cleft Palate J.*1990;27:382–385.
16. Tsouknidas A., et al. FEM assisted evaluation of materials for cranioplasty resulting mechanical behaviour and the neurocranial protection. *Bio-Medical Materials and Engineering* 21 (2011) 139–147.